

Research Article

Neonatal derived mesenchymal stem cell mesotherapy in androgenetic alopecia: a retrospective observational study and review of literature

Leelavathy Budamakuntla*, Eswari Loganathan, Shwetha Suryanarayana, Aparna Dongre

Department of Dermatology, Bangalore Medical College and Research Institute, Bangalore, Karnataka, India

Received: 17 April 2015

Accepted: 25 April 2015

*Correspondence:

Dr. Leelavathy Budamakuntla,

E-mail: drleelaskincare@rediffmail.com

Copyright: © the author(s), publisher and licensee Medip Academy. This is an open-access article distributed under the terms of the Creative Commons Attribution Non-Commercial License, which permits unrestricted non-commercial use, distribution, and reproduction in any medium, provided the original work is properly cited.

ABSTRACT

Background: Androgenetic alopecia has been a stressful condition for the patients and treating dermatologists alike. With the advent of stem cell therapy in various diseases, and lot of controversies and ethical issues related to it, mesenchymal stem cells MSC have passed the acid test successfully, though with many challenges. Since the stem cells in the hair follicle bulge and the dermal papilla play an important role in hair cycle and growth, introducing an external source of neonatal mesenchymal stem cells seems to be a possibility in the treatment of AGA. Aims: To know the benefits and safety of stem cell treatment in patients who underwent mesotherapy with neonatal MSC in order to establish the safety and efficacy in the treatment of AGA.

Methods: We collected data of 40 patients treated with mesoinjections of commercially prepared neonatal MSC, with AGA of grade 2 to 7. Before and after photographs, Patient (PtGA) and Physician (PGA) Global assessment scores were used to evaluate the treatment response.

Results: We found that 70% of the patients showed a mild response and 25% of them showed a moderate improvement in the hair growth and reduction in hair loss after 4 sittings of monthly duration. One subject showed an improvement of 72%. Patients had 6 month follow up. No major adverse events were observed.

Conclusions: Since this is an observational study, large randomized controlled studies, with longer follow ups is recommended to make MSC therapy a novel treatment option for AGA.

Keywords: Mesenchymal stem cells, Mesotherapy, Androgenetic alopecia

INTRODUCTION

Androgenetic alopecia AGA has become a stressful condition giving an impetus to constant research regarding its cause and management. It involves miniaturization of the terminal follicles into microscopic hair due to the action of dihydrotestosterone, an activated form of testosterone, by the enzyme 5 alpha reductase. Embryogenesis of hair is an excellent example of epithelio-mesenchymal interaction. Hair follicle is also a site for stem cells, allowing replacement of the follicle. Nestin-positive and K15-negative multipotent hair follicle stem cells are located above the hair follicle bulge, termed as hair follicle pluripotent stem (hfPS)

cells.¹ Stem cells in the bulge region of the hair follicle, as well as dermal papilla cells, play key role in the regulation of successive hair cycles. Bulge cells give rise to a progenitor population called the secondary germ cells, which reside adjacent to the bulge during telogen and produce the new hair shaft at anagen onset.²

Drugs and Hair restoration surgeries are currently widely known treatment options for AGA. Drugs are not permanent solution in AGA because discontinuing medications may progress the hair loss. Hair transplantation gives limited results because it depends on the methods and the survival of transplanted hair. To overcome these problems, introducing external source of

stem cells to regenerate hair can prove to be a much solicited therapeutic boon. To this end researchers have used, culture-expanded Mesenchymal Stem Cells (MSCs) to produce self-aggregated spheroidal Dermal Papilla Like Tissues (DPLTs) with the aid of a special culture condition *in vitro*.³ Hair inducing activity of self-aggregated DPLTs employing MSCs was tested in athymic mice and was found to have the same hair bulb structure inductive ability as natural DPLTs *in vitro*.³ As a result, Umbilical cord derived UC-MSCs and Bone marrow derived BM-MSCs may be an applicable and novel cell source for the generation of human hair.³

Stem cells have the capacity to self-renew and to give rise to cells of various lineages. Broadly speaking, there are two main types of stem cells, embryonic and non-embryonic. Embryonic Stem Cells (ESCs) are derived from the inner cell mass of the blastocyst and can differentiate into cells of all three germ layers.⁴ However teratoma formation and ethical controversy hamper their research and clinical application.⁴ On the other hand, non-embryonic stem cells also known as mesenchymal stem cells, are already somewhat specialized and have limited differentiation potential.⁴ They may be derived from adult tissue like bone marrow, adipose tissue etc. or derived from neonatal tissue like umbilical cord, cord blood, amnion or placenta. They are potential candidates in regenerative medicine.

There have been no published studies with regards to the use of neonatal derived mesenchymal stem cells in the treatment of AGA. But there have been anecdotal reports of the use of these stem cells in the form of mesotherapy in the treatment of AGA. So we did a retrospective observational study of subjects with AGA in whom we had used a commercial preparation of neonatal derived mesenchymal stem cells, in the form of mesoinjections, to determine the safety and therapeutic efficacy.

METHODS

This was a retrospective observational study of 40 subjects with androgenetic alopecia. This included 37 males and 3 females of age 20 to 50 years with grade 2 to grade 7 stage of AGA. Subjects with alopecia areata, alopecia totalis, telogen effluvium, anagen effluvium, acquired cicatricial alopecia, etc.; those with history of bleeding disorders/ active infection, on anti-coagulant medications (aspirin, warfarin, heparin), with keloidal tendency and subjects with history of psoriasis or lichen planus were not given stem cell mesotherapy.

Stem cells used for mesotherapy was a mixture of stem cells derived from umbilical cord, umbilical cord blood, amniotic fluid with certain growth factors. The product was certified negative for transfusion transmissible factors. It is a commercial product available in a sterile vial of 4 ml quantity. Cold chain was maintained during transportation of the product and mesotherapy was performed within 24 hours of preparation of the product.

Insulin syringes with needle length of 4 mm was used for injecting. Multiple microinjections were given at 0.5 cm interval intradermally into the affected area of scalp. Each patient underwent 4 sittings each at monthly intervals and was followed up for further 6 months. Improvement was assessed at each sitting using pre and post treatment photographs, patient global assessment scores PtGA and physician global assessment scores PGA.

RESULTS

There were a total of 40 subjects 37 males and three females whose assessment was done. They were in the age group of 20 to 50 years, with the youngest being 25 years and the oldest being 50. Sixty five percent (26 subjects) of them had Grade 3 alopecia, followed by 10 subjects with grade2, and two subjects with grade 4 and two with grade 5 alopecia. 30 subjects gave a family history of AGA. All of them gave history of using other medical treatments for AGA, with 22 of them having used topical minoxidil 5% solution, 13 of them biotin based hair supplements and remaining 5 of them having used indigenous medications like hair oil etc. The PGA and PtGA scores are shown in Figure 1. Both PtGA and PGA scores were comparable.

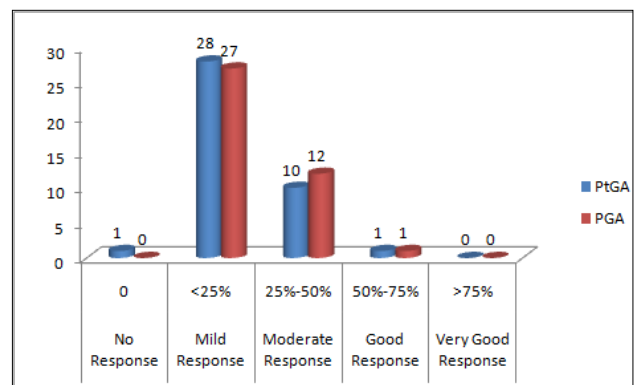


Figure 1: Physician and patient global assessment scores, PGA & PtGA.

Around 28 subjects showed less than 25% improvement (mild response). 10 subjects showed a moderate response (25-50% response). Before and after photographs showing improvement are seen in Figures 2, 3, 4 & 5.

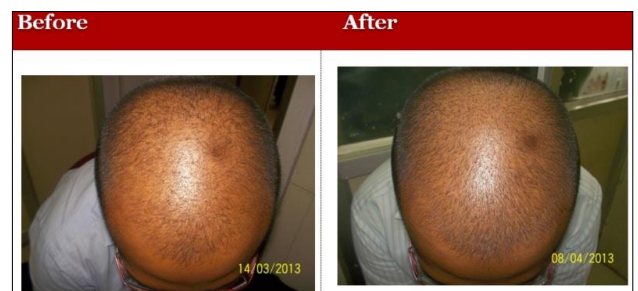

Figure 2: Patient 1: Before and after neonatal MSC therapy.

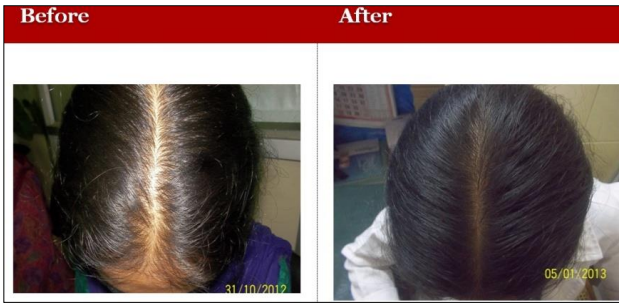

Figure 3: Patient 2: Before and after neonatal MSC therapy.

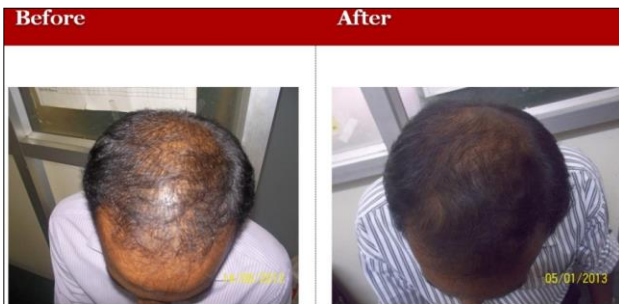

Figure 4: Patient 3: Before and after neonatal MSC therapy.

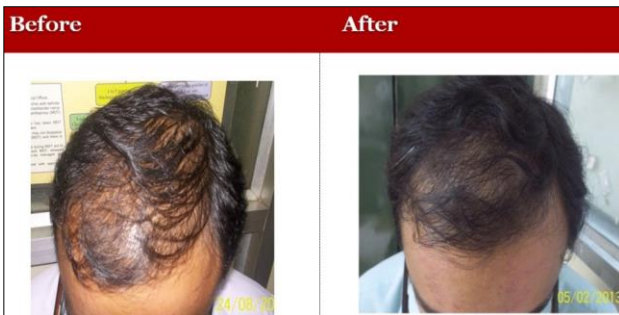

Figure 5: Patient 4: Before and after neonatal MSC therapy.

One patient had a mild anaphylactic reaction 3 to 4 hours after the procedure with mild urticarial rashes, which subsided on antihistamine treatment. Apart from this no other adverse events were recorded.

DISCUSSION

In this study we found that stem cell mesotherapy using neonatal derived MSC gave a mild to moderate improvement in the hair growth in AGA subjects and prevented hair loss to a substantial level. It proved to be a very safe mode of treatment with hardly any adverse events.

MSCs can be isolated from various tissues such as adipose tissue, peripheral blood, umbilical cord, amnion and placenta and there by classified into adult derived and neonatal derived mesenchymal stem cells. In 2006,

the International Society of Cellular Therapy defined MSCs by the following three criteria:⁵ (1) MSCs must be adherent to plastic under standard tissue culture conditions; (2) MSCs must express certain cell surface markers such as CD73, CD90, and CD105, and lack expression of other markers including CD45, CD34, CD14, or CD11b, CD79 alpha or CD19 and HLA-DR surface molecules; (3) MSCs must have the capacity to differentiate into osteoblasts, adipocytes, and chondroblasts under in vitro conditions.

The therapeutic effects of MSC are mainly attributed to their four important biological properties:⁴ (1) the ability to home to sites of inflammation following tissue injury when injected intravenously (2) the ability to differentiate into various cell types (3) the ability to secrete multiple bioactive molecules capable of stimulating recovery of injured cells and inhibiting inflammation (4) the lack of immunogenicity and the ability to perform immunomodulatory functions.

Based on these properties we can speculate how injecting neonatal derived mesenchymal stem cells can stimulate hair growth in androgenetic alopecia. 1) They home to the hair follicle bulge or the dermal papilla where the pathogenesis of AGA is centered. 2) Hair follicle development being an excellent example of epithelio-mesenchymal interaction, they are capable of differentiating into all components of hair follicle. 3) By secreting multiple bioactive molecules like growth factors, cytokines, chemokines which may help in sending signals for hair growth, there by stimulating the existing stem cells in the bulge 4) There are no adverse reactions like immune rejection seen after mesotherapy with stem cells 5) They have known anti-apoptotic and regeneration-stimulating effects.⁶ These effects can be either direct or indirect or both: direct by causing intracellular signaling or indirect by causing another cell in the microenvironment to secrete functionally active agent⁴. In mesotherapy we give repeated multiple injections there by stimulating the dermal papilla cells. The Dermal Papilla (DP), a cluster of specialized fibroblasts, regulates the growth and activity of the various cells in the follicle, thereby, plays a key role in the regulation of hair cycle and growth.⁷ Hair follicle regeneration begins when signals from the mesenchyme derived DP cells reach multipotent epidermal stem cells in the bulge region.⁸

A significant advantage of these neonatal tissues is their ready availability, thus avoiding invasive procedures and ethical problems. Moreover, birth-associated tissues harbour a variety of embryonic or premature cell populations including MSC, endothelial stem/ progenitor cells and hematopoietic stem cells (CD34+, CD133+).⁹ It is also suggested that MSC from these neonatal tissues may have additional capacities in comparison to MSC derived from adult sources with respect to improved proliferative capacity, life span and differentiation potential.⁹

At the same time there are many challenges posed by the MSCs:⁴ 1) though there are few or no adverse events as in this study, they have been reported to promote tumor growth¹⁰ and metastases.¹¹ 2) There may be risk of microbial contamination during the various phases of harvesting the stem cells.⁴ 3) During in vitro expansion of MSC, continuous passaging of MSCs could lead to cell transformation. To reduce malignant transformation of human MSCs, meticulous attention must be taken to prevent cell senescence and limit the number of passaging.⁴ 4) They are immune privileged cells because of low expression of MHC-I molecules.¹² Thus both autologous and allogeneic MSCs can be used in the clinical setting. However, which one to prefer needs further investigation. 5) Methods and criteria for the culture, storage, shipping, and administration of MSCs must be standardized and regularized.⁴

This study is a retrospective observation of effects of neonatal MSC in the treatment of AGA. Trichoscan and hair count will be better methods to assess the treatment response which are lacking in this study. Patients were followed up for just 6 months, where in a long term follow up will give better evidence of the proliferative effects of the injected MSCs and also reveal long term adverse events if any. Therefore more randomized, controlled, multicentre clinical trials, with longer follow up in order to establish the safety and efficacy is recommended.

Neonatal derived MSCs have proved a very exciting and promising avenue in regenerative medicine. This study has shown a mild to moderate improvement in the hair growth with little or no adverse events. A more standardized method of preparation, administration, evidence based clinical trials and longer follow ups may throw more light on this subject and light up the lives of many people suffering from AGA.

Funding: No funding sources

Conflict of interest: None declared

Ethical approval: Not required

REFERENCES

1. Amoh Y, Li L, Katsuoka K, Hoffman RM. Embryonic development of hair follicle pluripotent stem (hfPS) cells. *Med Mol Morphol*. 2010 Jun;43(2):123-7.
2. Ito M, Kizawa K, Hamada K, Cotsarelis G. Hair follicle stem cells in the lower bulge form the secondary germ, a biochemically distinct but functionally equivalent progenitor cell population, at

- the termination of catagen. *Differentiation*. 2004;72(9-10):548-57.
3. Yoo BY, Shin YH, Yoon HH, Seo YK, Song KY, Park JK. Application of mesenchymal stem cells derived from bone marrow and umbilical cord in human hair multiplication. *J Dermatol Sci*. 2010 Nov;60(2):74-83.
 4. Wang S, Qu X, Zhao RC. Clinical applications of mesenchymal stem cells. *J Hematol Oncol*. 2012;5:19.
 5. Dominici M, Le Blanc K, Mueller I, Slaper-Cortenbach I, Marini F, Krause D, et al. Minimal criteria for defining multipotent mesenchymal stromal cells. The International Society for Cellular Therapy position statement. *Cytotherapy*. 2006;8:315-7.
 6. Parekkadan B, van Poll D, Suganuma K, Carter EA, Berthiaume F, Tilles AW, et al. Mesenchymal stem cell-derived molecules reverse fulminant hepatic failure. *PLoS One*. 2007;2:e941.
 7. Kwack MH, Sung YK, Chung EJ, Im SU, Ahn JS, Kim MK, et al. Dihydrotestosterone-inducible dickkopf 1 from balding dermal papilla cells causes apoptosis in follicular keratinocytes. *J Invest Dermatol*. 2008;128:262-9.
 8. Dhurat R, Sukesh MS, Avhad G, Dandale A, Pal A, Pund P. A randomized evaluator blinded study of effect of microneedling in androgenetic alopecia: a pilot study. *Int J Trichol*. 2013;5:6-11.
 9. Hass R, Kasper C, Böhm S, Jacobs. Different populations and sources of human mesenchymal stem cells (MSC): a comparison of adult and neonatal tissue-derived MSC. *Cell Commun Signal*. 2011;9:12.
 10. Djouad F, Plerce P, Bony C, Tropel P, Apparailly F, Sany J, et al. Immunosuppressive effect of mesenchymal stem cells favors tumor growth in allogeneic animals. *Blood*. 2003;102:3837-44.
 11. Karnoub AE, Dash AB, Vo AP, Sullivan A, Brooks MW, Bell GW, et al. Mesenchymal stem cells within tumour stroma promote breast cancer metastasis. *Nature*. 2007;449:557-63.
 12. Guo M, Sun Z, Sun QY, Han Q, Yu CL, Wang DH, et al. A modified haploidentical nonmyeloablative transplantation without T cell depletion for high-risk acute leukemia: successful engraftment and mild GVHD. *Biol Blood Marrow Transplant*. 2009;15:930-7.

Cite this article as: Budamakuntla L, Loganathan E, Suryanarayana S, Dongre A. Neonatal derived mesenchymal stem cell mesotherapy in androgenetic alopecia: a retrospective observational study and review of literature. *Int J Sci Rep* 2015;1(1):32-5.