

Case Report

A case of lipoma in lateral anterior neck: a common entity at an uncommon location

Deepshikha Rana*, Sujata Raychaudhuri, Sheetal Arora

Department of Pathology, ESIC Medical College and Hospital, Faridabad, Haryana, India

Received: 14 April 2017

Accepted: 10 May 2017

*Correspondence:

Dr. Deepshikha Rana

E-mail: ranadeepshikha@yahoo.com

Copyright: © the author(s), publisher and licensee Medip Academy. This is an open-access article distributed under the terms of the Creative Commons Attribution Non-Commercial License, which permits unrestricted non-commercial use, distribution, and reproduction in any medium, provided the original work is properly cited.

ABSTRACT

Lipoma is the most common benign mesenchymal tumor of adipose tissue. Their occurrence in head and neck is relatively rare. Lipomas in the neck region are rare tumors that usually present as slowly growing painless masses, found in the lateral portions of the neck. Here, we report a case of lipoma lying over the left lobe of thyroid above the sternal notch in a 41-year old man. Swelling was gradually progressive in size since 2 years with no other complaints. Swelling was firm in consistency, mobile, non-tender and not moving with deglutition. It was clinically diagnosed as thyroid neoplasm/ cystic swelling and later on cytological and histopathological examination was performed which revealed benign lipoma. The purpose of this case report is to recognise rare lipomas that occur in unusual locations in the head and neck in order to identify them when they can cause diagnostic problems.

Keywords: Thyroid, Lipoma, Neck

INTRODUCTION

Head and neck region is the most complicated area in our body with different important structures. Numerous swellings of different etiology and presentations can occur in this region. Classification of swellings are based on etiology-congenital or acquired, site-midline or lateral and consistency- cystic, firm or hard. Lipomas are the most common benign soft tissue mesenchymal tumor originating from adipose tissue.¹ Mostly lipomas are small, subcutaneous, circumscribed and asymptomatic with 15-20% of the cases involving head and posterior neck region.² We are reporting a case of swelling anterior neck with unusual site of presentation and clinical details, posing a challenge for the diagnosis and management.

CASE REPORT

A forty-one-year-old male patient came to the ENT department with complaints of swelling in the neck since 2 years. Swelling was gradually progressive in size with

no complaints of pain, loss of weight or appetite, difficulty in swallowing or speech. He was a known smoker. On examination a 2×2 cm swelling was seen over the left lobe of thyroid about 2 cm above the sternal notch. Swelling was firm in consistency, mobile, non-tender and not moving with deglutition. Clinical diagnosis of thyroid neoplasm/ cystic swelling was made.

Cytological examination reveals mature adipose tissue. Features were suggestive of lipoma. Excision biopsy was performed.

Grossly, the mass measured 2×1 cms which was lobulated and partially encapsulated. Outer surface was smooth and shiny. Cut surface was soft, yellowish greasy. Multiple sections were taken including capsule. No thyroid tissue/ cyst were identified. All sections were stained by hematoxylin and eosin stain.

Histopathological examination revealed mature adipose tissue surrounded by thin connective tissue capsule in all

sections. No thyroid tissue was identified. Final diagnosis of lipoma was made.

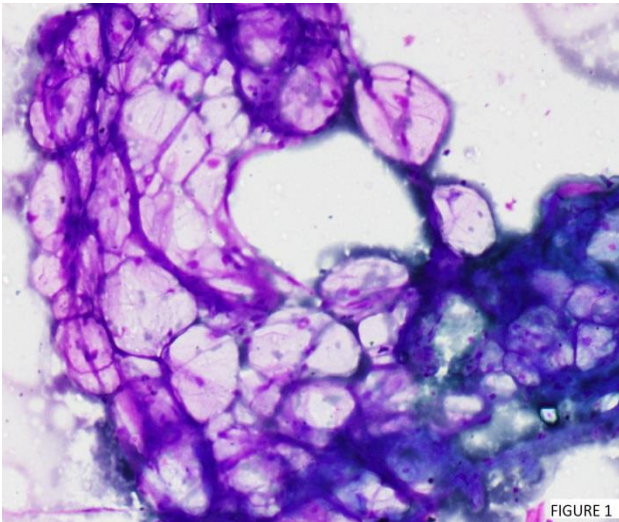


Figure 1: Lipoma anterior neck region shows mature adipocytes (giemsa staining, magnification 40X).

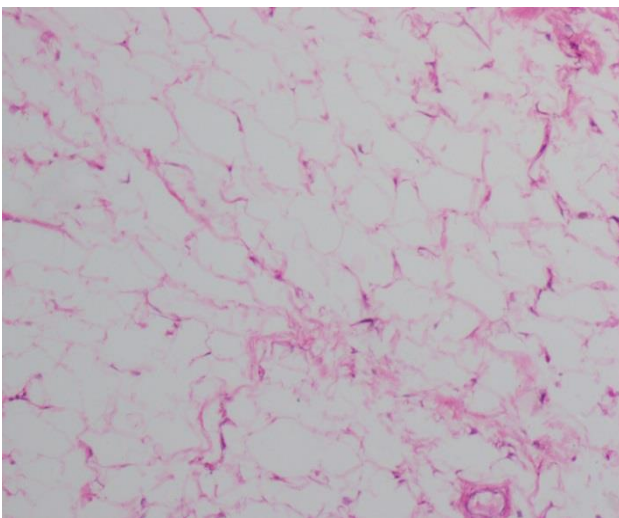


Figure 2: Lipoma anterior neck region shows mature adipocytes (hematoxylin and eosin, magnification 20X).

DISCUSSION

The presence of a lump in the neck is a common problem. Characteristics that help diagnose neck lumps include age of patient, site, size, consistency, colour, attachment, pulsation and tenderness. Inflammatory and congenital lumps are most common in young adults and children. In adults a persistent lump is likely to be a tumour of some type and malignancy must be excluded. Common lumps that can occur anywhere in the neck or in fact anywhere in the body include lipomas and sebaceous cysts. Benign lipomas are the most common soft tissue tumour in the body (5%), out of which 13% of lipomas occur in the head and neck.¹ Amongst the head and neck lipomas,

commonest location is posterior neck. Anterior neck is a rare location for head and neck lipoma.³ There is an equal distribution between the sexes, with presentation most commonly in the fifth and sixth decade and in a subcutaneous location.² Our case is an adult male presenting with an anterior neck mass which is a rare site for lipomas to occur.

Lipomas are soft, mobile, non-tender slow growing masses. Lipomas can be singular or multiple & are asymptomatic unless they are large in size and compressing neurovascular structures. Besides producing aesthetic consequences, lipomas can also exert pressure on surrounding structures. In our case patient was totally asymptomatic with a small singular swelling in the anterior region of neck. Considering the site of the swelling, clinical diagnosis of thyroid neoplasm/ cystic swelling was made. The swelling was non-fluctuant and did not move on deglutition or protrusion of tongue.

Differential diagnosis of neck swelling can be branchial cysts, epidermal cysts, thyroglossal cysts, haemangioma, lymph node and normal muscle. According to the site, age, duration and symptoms of the patient our differential included lymph node, thyroid neoplasm, lipoma and sebaceous cyst. Cytological examination was performed to narrow down our differential. Cytological examination suggested lipoma. Histopathological examination was done to confirm our diagnosis. It revealed lipoma. Final diagnosis of lipoma was given.

Common location for lipoma are back, arm, shoulder, anterior chest wall, thigh, abdominal wall, legs, forehead and face in decreasing order of frequency. Lipoma may be located in all parts of the body and can be confused clinically with soft tissue mass.^{4,5} Rarely they develop in the anterior neck, infra-temporal fossa and in or around the oral cavity, pharynx, larynx and parotid gland.^{6,7}

Surgical excision of lipoma is the treatment of choice. Mostly surgery is done for cosmetic reasons, but other indications can be large size causing pressure symptoms and for malignancy. Recurrences are very commonly observed. Although being an encapsulated mass, proper enucleation can prevent recurrence. Neck swellings are observed on routine basis and they can have a very wide differential. Mostly these are easily diagnosed clinically but pose a problem when located at rare sites like our case which simulated thyroid neoplasm/ cyst clinically. So investigations like cytology and histopathology can aid in proper and timely diagnosis. The diagnosis of a benign lipoma can alter a treatment approach, prognosis and correct an erroneous clinical impression. Rare lipomas in the anterior neck, infratemporal fossa, nasopharynx, cheek, tongue, and larynx must be presented.

Funding: No funding sources

Conflict of interest: None declared

Ethical approval: Not required

REFERENCES

1. Ahuja AT, King AD, Kew J, King W, Metreweli C. Head and Neck Lipomas: Sonographic Appearance. *Am J Neuroradiol.* 1998;19:505-8.
2. Barnes L. Tumors & tumor like lesions of the head & neck: In: Barnes L, editor. *Surgical Pathology Of The Head & Neck.* New York, NY: Dekker; 1985: 747-758.
3. Rupa S, Dutta B, Singh SP, Rathore A. Giant anterior neck Lipoma with mediastinal extension: A rare case report. *Int J of Sci Res Publications.* 2013;3(8):2250-3153.
4. Vargas Fernández JL, Lorenzo Rojas J, Aneiros Fernández J, Sainz Quevedo M. Dermoid cyst of the floor of the mouth. *Acta Otorrinolaringol Esp.* 2007;58(1):31-3.
5. Lakshmi S, Somashekara KG, Priya NS. Epidermoid cyst of tongue. *Otorhinolaryngol Clin.* 2011;3(2):122-4.
6. Meyer I. Dermoid cysts (dermoids) of the floor of the mouth. *Oral Surg Oral Med Oral Pathol.* 1955;8:1149-64.
7. Corrêa MS, Fonoff Rde N, Ruschel HC, Parizotto SP, Corrêa FN. Lingual epidermoid cyst- case report in an infant. *Pediatr Dent.* 2003;25(6):591-3.

Cite this article as: Rana D, Raychaudhuri S, Arora S. A case of lipoma in lateral anterior neck: a common entity at an uncommon location. *Int J Sci Rep* 2017;3(6):182-4.