

## Case Report

# A rare case of male Turner syndrome for penetrating keratoplasty

Shobha Ravishankar\*

Department of Anaesthesiology, Medical Research Foundation, Chennai, Tamil Nadu, India

**Received:** 08 August 2017

**Revised:** 28 August 2017

**Accepted:** 29 August 2017

**\*Correspondence:**

Dr. Shobha Ravishankar,

E-mail: [drsrs@snmail.org](mailto:drsrs@snmail.org)

**Copyright:** © the author(s), publisher and licensee Medip Academy. This is an open-access article distributed under the terms of the Creative Commons Attribution Non-Commercial License, which permits unrestricted non-commercial use, distribution, and reproduction in any medium, provided the original work is properly cited.

### ABSTRACT

Turner syndrome (TS) is a complex genetic disorder. These abnormalities especially those relating to the airway and cardiovascular system, pose a challenge to the anaesthesiologist. The main anatomic-physiological changes pertaining to the anaesthesiologist include a short neck, maxillary and mandibular hypoplasia which might be responsible for difficult airway. The shorter length of trachea as well as higher location of its bifurcation predispose to bronchial intubation and accidental endotracheal extubation when tracheal cannula is under traction. The presence of cardiopathies, endocrine and gastro intestinal disorders, liver and kidney changes as well as osteoarticular involvement besides ophthalmologic and hearing impairments are very frequent and should be detected during pre-anaesthetic evaluation. The incidence of TS is variously reported as 1:3000 to 1:10000 live (female) births. Very few cases of male turner have been reported in literature.

**Keywords:** Turner syndrome, Genetic, Difficult airway

### INTRODUCTION

45,X/46,XY mosaicism, also known as XO/XY mosaicism and mixed gonadal dysgenesis, is a rare disorder of sex development in humans associated with sex chromosome aneuploidy and mosaicism of the Y chromosome.<sup>1</sup> This is called a mosaic karyotype because, like tiles in mosaic floors or walls, there is more than one type of cell.

The clinical manifestations are highly variable, ranging from partial virilisation and ambiguous genitalia at birth, to patients with completely male or female gonads. Most individuals with this karyotype have apparently normal male genitalia, and a minority with female genitalia, with a significant number of individuals showing genital abnormalities or intersex characteristics. A significantly higher than normal number of other developmental abnormalities is also found in individuals with XO/XY mosaicism. Psychomotor development is normal. A rare form of TS has also been described in males.<sup>2,3</sup>

### CASE REPORT

A 21 year old male diagnosed as TS on preanaesthetic evaluation was posted for tectonic penetrating keratoplasty following a failed graft. The primary corneal opacity was secondary to trauma with a cricket ball. He had undergone two penetrating keratoplasties under local anaesthesia in some other hospital and presented to our institution with a failed graft. This being the third surgery, patient was apprehensive and hence surgery was scheduled under general anaesthesia.

On examination, patient had a short stature and near normal mentation. The secondary sexual characters were not well developed to match his age. Webbing of neck was noted and the neck movements were also restricted. Airway examination revealed a decreased thyromental distance (of just two fingers) and Mallampatti grade was III.

Systemic examination was normal except that he had a soft systolic murmur on auscultation. Haematological results were unremarkable. Chest X-ray was normal. ECG showed sinus bradycardia. Echocardiogram revealed mitral valve prolapse and moderate mitral regurgitation. The specific findings were incurving of both little fingers and notable cubitus valgus. An informed consent was obtained before subjecting the patient to general anaesthesia.

Patient was adequately fasted following universal fasting guidelines. Pre-medication was IM glycopyrrolate. A 20G IV cannula was inserted and routine monitoring were attached (ECG, NIBP, SaO<sub>2</sub> and EtCO<sub>2</sub>). Anaesthesia was induced with I.V. Propofol 2 mg/kg and I.V. Fentanyl 1 mg/kg.

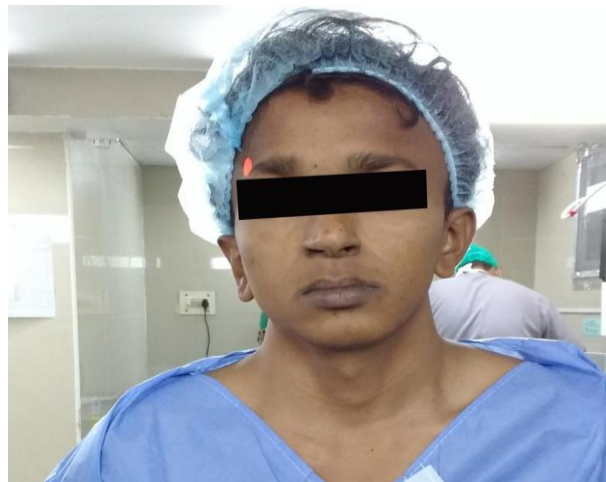As difficult intubation was anticipated the plane of anaesthesia was deepened with bag-mask ventilation using 5% sevoflurane as dial concentration. Laryngoscopy was performed and the presented view was graded as Cormack- Lehane 3. A flexo metallic size 7 (ID) tube was threaded on to the bougie and manipulated under epiglottis. Intubation was successful in first attempt. The correct placement of the tube was confirmed by auscultation and capnography. Patient was paralyzed with vecuronium bromide (1 mg/kg) and volatile of choice was desflurane. Patient remained stable throughout the intraoperative period. The duration of the surgery was about two hours. At the end of the surgery the residual neuromuscular paralysis was reversed and patient was extubated completely awake.

## DISCUSSION

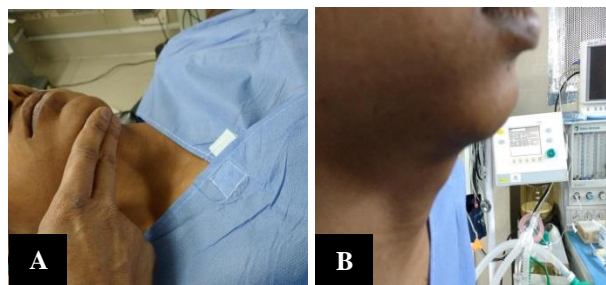
45,X/46,XY mosaicism is associated with a broad spectrum of phenotypes ranging from apparently normal male development to individuals with incomplete sexual determination and clinical signs of Turner Syndrome in both males and females. The most common presentation among individuals with a 45,X/46,XY karyotype is sexual ambiguity accounting for approximately 60% of cases, while the least common category of 45,X/46,XY patients consist of those with bilaterally descended testes found in 11-12%.

In a normal situation, all the cells in an individual will have 46 chromosomes with one being X and one Y or with two Xs. However, during this complicated early copying process (DNA replication and cell division), one chromosome may be lost. In 45,X/46,XY, most or all of Y chromosome is lost in one of the newly created cells. All the cells then made from this cell will lack the Y chromosome. Those cells created from these cells that have not lost the Y chromosome will be XY.<sup>4</sup> The 46,XY cells will continue to multiply at the same time as the 45,X cells multiply. The embryo, then the fetus and then the baby will have what is called a 45,X/46,XY constitution. This is called a mosaic karyotype, because

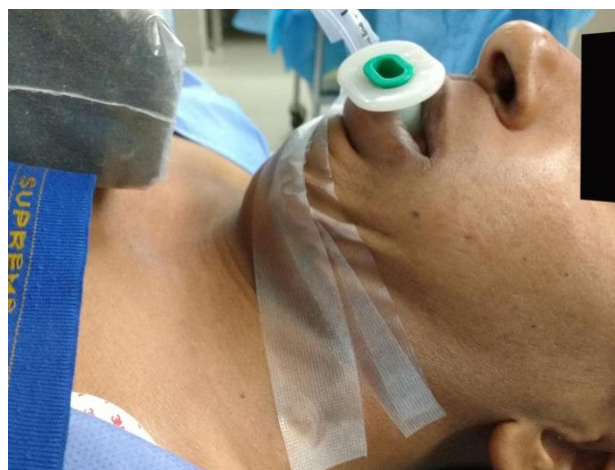like tiles in mosaic floors or walls, there is more than one type of cell.



**Figure 1: Webbing of neck.**

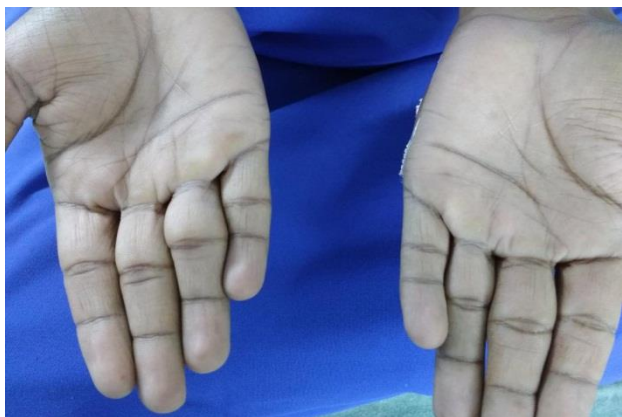

**Figure 2: (A and B) Decreased thyro-mental distance.**



**Figure 3: Difficult airway.**

There are many chromosomal variations that cause the 45,X/46,XY karyotype, including malformation (isodicentricism) of the Y chromosomes, deletions of Y chromosome or translocations of Y chromosome segments.<sup>5</sup> These rearrangements of the Y chromosome can lead to partial expression of the SRY gene which may lead to abnormal genitals and testosterone levels.



**Figure 4: Incurving little fingers.**

Although similar in some ways to true hermaphroditism, the conditions can be distinguished histologically and by karyotyping.<sup>6</sup> The observable characteristics (phenotype) of this condition are highly variable, ranging from gonadal dysgenesis in males, to Turner-like females and phenotypically normal males.<sup>7,8</sup> The most common presentation of 45,X/46,XY karyotype is phenotypically normal male, next being genital ambiguity.<sup>9</sup>

The male turner syndrome is one of the rarest presentations and with its complexities calls for a through anaesthetic planning.

*Funding: No funding sources*

*Conflict of interest: None declared*

*Ethical approval: Not required*

## REFERENCES

1. 45, X/46,XY including Y chromosome rearrangements. Available at: <http://www.rare->

[chromo.org/information/Chromosome\\_Y/45X%2046XY%20including%20Y%20chromosome%20rearrangements%20FTNW.pdf](http://chromo.org/information/Chromosome_Y/45X%2046XY%20including%20Y%20chromosome%20rearrangements%20FTNW.pdf). Accessed on 4 August 2017.

2. Goodman RM, Gorlin RJ. The face in genetic disorders. St.Louis: C.V. Mosby Co; 1970: 168-169.
3. Vaughan VC, McKay RJ, Behronan R. Nelson's Text Book of Paediatrics. 11th ed. Philadelphia: W.B. Sanders Co; 1979: 366-367.
4. 45,X/46,XY Mosaicism: Report of 27 Cases (<http://pediatrics.aappublications.org/content/104/2/304.short>). Pediatrics. 1999;104(2):304-8.
5. Lindhardt JM, Hagen CP, Rajpert-De Meyts E, et al. 45,X/46,XY mosaicism: phenotypic characteristics, growth, and reproductive function - a retrospective longitudinal study. Clin Endocrinol Metab. 2012;97(8):1540-9.
6. Kim KR, Kwon Y, Joung JY, Kim KS, Ayala AG, Ro JY. True hermaphroditism and mixed gonadal dysgenesis in young children: a clinicopathologic study of 10 cases. Mod Pathol. 2002;15(10):1013-9.
7. Chang HJ, Clark RD, Bachman H (1990). "The Phenotype of 45, X/46, XY mosaicism: An analysis of 92 prenatally diagnosed cases". Am J Human Genetics. 1990;46(1):156-67.
8. Hsu LY. Prenatal diagnosis of 45,X/46,XY mosaicism - a review and update. Prenat Diagn. 1989;9(1):31-48.
9. Efthymiadou A, Stefanou EG, Chrysis D. 45,X/46,XY mosaicism a cause of short stature in males. Hormones (Athens). 2012;11(4):501-4.

**Cite this article as:** Ravishankar S. A rare case of male Turner syndrome for penetrating keratoplasty. Int J Sci Rep 2017;3(10):274-6.