

## Case Report

# Iatrogenic jejunal perforation while FJ tube re-insertion: a rare complication of feeding jejunostomy tube reinsertion

Bappaditya Har\*, Raunak Shinde, Debraj Saha, Bitan Kumar Chattopadhyay

Department of General Surgery, IPGMER & SSKM Hospital, Kolkata-20, West Bengal, India

**Received:** 19 February 2015

**Accepted:** 03 April 2015

**\*Correspondence:**

Dr. Bappaditya Har,

E-mail: [adi.bappaditya7@gmail.com](mailto:adi.bappaditya7@gmail.com)

**Copyright:** © the author(s), publisher and licensee Medip Academy. This is an open-access article distributed under the terms of the Creative Commons Attribution Non-Commercial License, which permits unrestricted non-commercial use, distribution, and reproduction in any medium, provided the original work is properly cited.

### ABSTRACT

Feeding jejunostomy a good way to deliver enteral nutrition in a number of conditions with a very low complication rate and very cost-effective way to deliver nutrition in our part of country where PEG is not widely available. FJ is commonly done with Foley's catheter, Ryle's tube, T-tube. In some situations (clogging/expulsion), we have to change the tube through the mature tract. But, it is utmost important that proper lubrication of the tube & gentle attempt should be made and excessive thrust must not be made. Any difficulty while introduction should be thoroughly evaluated. Here we present a rare complication of FJ tube reinsertion leading to jejunal perforation.

**Keywords:** FJ complication, Jejunal perforation, Iatrogenic perforation

### INTRODUCTION

Percutaneous Endoscopic Gastrostomy (PEG) and Feeding Jejunostomy (FJ) are well-established methods of providing access to the gastrointestinal tract to administer enteral nutrition and medication over prolonged periods of time in patients with neurological disorders. There is evidence to demonstrate that a FJ is a safe procedure with associated reductions of infective and metabolic complications when compared with total parenteral nutrition. Although a relatively simple technical procedure it is not without risk or complication.

We report a rare complication secondary to re-insertion of a FJ leading to jejunal perforation.

### CASE REPORT

A 21 years old female patient with corrosive acid ingestion was admitted under us for insertion of FJ tube for provision of temporary nutrition due to oesophageal

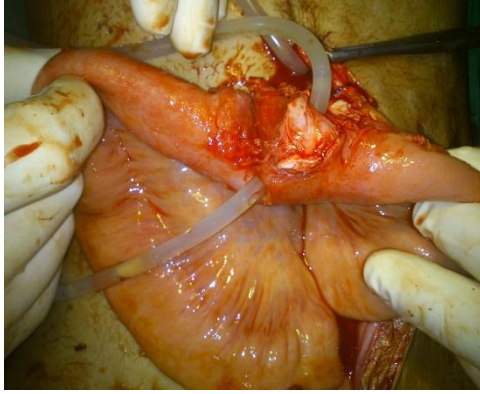
stricture. We did a classic Witzel's procedure with No. 20 Foley's catheter.

Postoperative period was uneventful & the FJ tube was functioning properly.

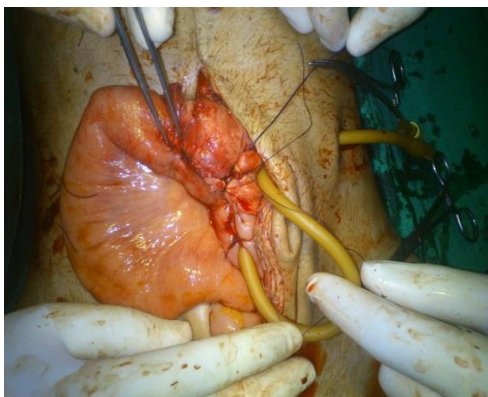
We discharged the patient & referred for regular oesophageal dilatation. Seven weeks later the patient presented in our Emergency with severe pain abdomen & features of peritonitis. Straight X-ray abdomen showed free gas under both domes of diaphragm.

On history, patient attended local hospital due to clogging of the tube where they attempted reinsertion with an 18 Fr Ryle's tube. We planned for exploratory laparotomy & it showed the Ryle's tube was wandering free in the peritoneum after perforating the jejunal wall (Figure 1).

We repaired the perforated site & created a new FJ, distal to the previous site (Figure 2).



**Figure 1: Intraoperative photograph showing jejunum is perforated by the Ryle's tube.**



**Figure 2: Intraoperative photograph after repair the perforation & creating FJ at a new site.**

## DISCUSSION

Common complication of feeding jejunostomy are mechanical complication (dislocation, obstruction, migration), Infections, gastrointestinal symptoms (nausea, vomiting diarrhoea, constipation,) and metabolic / electrolyte disturbances.<sup>1-8</sup> The incidence of major complications is 8% to 20%. Mechanical complications are difficult to assess clinically. The threshold for imaging and operative intervention should be low in such patients. Despite our repeated efforts to diagnose a tube-related complication we were unable to do so until surgical exploration. This case demonstrates the need for good clinical judgement and a high index of suspicion for tube-related complications, especially in situations where both clinical assessment of the patient and the appropriate investigations fail to provide adequate evidence of the problem. A possible explanation for such a perforation is

the presence of localised pressure necrosis of the bowel wall caused by constant pressure exerted by the tip of the feeding tube on a single point of the bowel wall with excessive thrust applied while re-insertion. Attempts to prevent this occurring are undertaken by using appropriately designed soft-tipped tubes and by fixing the bowel wall to the anterior abdominal wall to prevent any rotation & applying gentle technique while reinsertion.

*Funding: No funding sources*

*Conflict of interest: None declared*

*Ethical approval: Not required*

## REFERENCES

1. Tapia J, Murguia R, Garcia G, de los Monteros PE, Oñate E. Jejunostomy: techniques, indications, and complications. *World J Surg.* 1999;23:596-602.
2. Cataldi-Betcher EL, Seltzer MH, Slocum BA, Jones KW. Complications occurring during enteral nutrition support: a prospective study. *JPEN J Parenter Enteral Nutr.* 1983;7:546-52.
3. Cogen R, Weinryb J, Pomerantz C, Fenstermacher P. Complications of jejunostomy tube feeding in nursing facility patients. *Am J Gastroenterol.* 1991;86:1610-3.
4. Whiteley GS, Baildam AD, Walter DP, Taylor TV. Complications of percutaneous endoscopic enterostomy tubes. *Surg Laparosc Endosc.* 1992;2:227-9.
5. Shike M, Latkany L, Gerdes H, Bloch AS. Direct percutaneous endoscopic jejunostomies for enteral feeding. *Gastrointest Endosc.* 1996;44:536-40.
6. Eddy VA, Snell JE, Morris JA. Analysis of complications and long term outcome of trauma patients with needle catheter jejunostomy. *Am Surg.* 1996;62:40-4.
7. Prahlow JA, Barnard JJ. Jejunostomy tube failure: malnutrition caused by intraluminal antegrade jejunostomy tube migration. *Arch Phys Med Rehabil.* 1998;79:453-5.
8. De Gottardi A, Krahenbuhl L, Farhadi J, Gernhardt S, Schäfer M, Büchler MW. Clinical experience of feeding through a needle catheter jejunostomy after major abdominal operations. *Eur J Surg.* 1999;165:1055-60.

**Cite this article as:** Har B, Shinde R, Saha D, Chattopadhyay BK. Iatrogenic jejunal perforation while FJ tube re-insertion: a rare complication of feeding jejunostomy tube reinsertion. *Int J Sci Rep* 2015;1(1):92-3.