

## Case Report

# A peculiar case of cancer en cuirasse in adenocarcinoma rectum

Parul Gupta<sup>1</sup>, Ashish Nigam<sup>1</sup>, Anil K. Dhull<sup>1</sup>, Arpit Mittal<sup>2\*</sup>

<sup>1</sup>Department of Radiation Oncology, <sup>2</sup>Department of Pediatrics, Pt. B. D. Sharma PGIMS, Rohtak, Haryana, India

**Received:** 16 February 2020

**Accepted:** 16 March 2020

**\*Correspondence:**

Dr. Arpit Mittal,

E-mail: [mittal.dr.arpit@gmail.com](mailto:mittal.dr.arpit@gmail.com)

**Copyright:** © the author(s), publisher and licensee Medip Academy. This is an open-access article distributed under the terms of the Creative Commons Attribution Non-Commercial License, which permits unrestricted non-commercial use, distribution, and reproduction in any medium, provided the original work is properly cited.

### ABSTRACT

Cancer en cuirasse in a case of primary adenocarcinoma rectum is an exceedingly rare phenomenon which is scarcely seen in isolated case reports only. It is a specific morphological variant of cutaneous metastasis characterised by diffuse induration and oedema of cutis which is studded with carcinomatous lesions. Cutaneous metastases often occur in elderly individuals in their sixth decade or later. Herein we present a case of carcinoma en cuirasse arising in a young female who was operated for adenocarcinoma rectum.

**Keywords:** Cancer en cuirasse, Cutaneous metastasis, Adenocarcinoma rectum

### INTRODUCTION

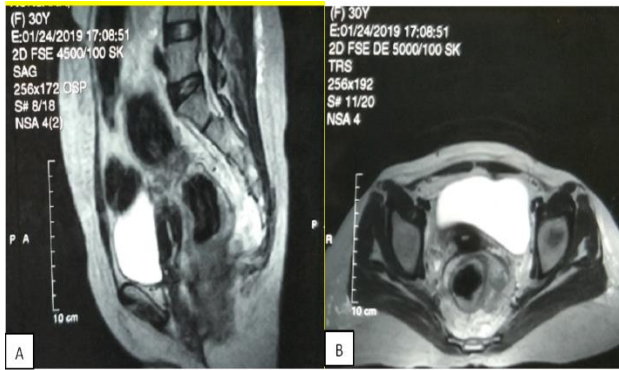
Cancer en cuirasse is a specific morphological variant of cutaneous metastasis characterised by diffuse induration and oedema of cutis which is studded with carcinomatous lesions.<sup>1</sup> Cutaneous metastases are more prevalent in elderly individuals in their sixth decade or older.<sup>2</sup> Cancer en cuirasse signifies rapidly advancing and widespread disease with dismal prognosis.<sup>3</sup> Its presence in a case of primary adenocarcinoma rectum is an exceedingly rare phenomenon which is documented in isolated case reports only.<sup>4</sup>

### CASE REPORT

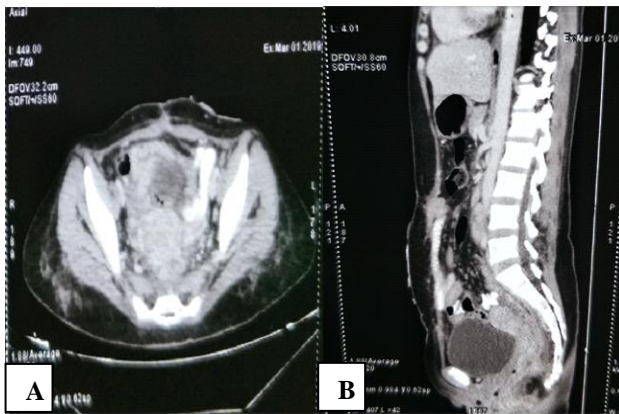
A 34 years old female presented with chief complaints of bleeding per rectum, constipation, loss of appetite and weight loss for past five months. Bleeding per rectum was insidious in onset, painless, intermittent in nature and consisted of fresh blood at the end of defecation. Constipation was progressively increasing for past 5 months and was associated with intermittent abdominal pain, nausea and vomiting. There were no other significant systemic illnesses. Per-rectal examination revealed a partially obstructing irregular mass, 4 cm from anal verge and along entire wall circumference. Magnetic

resonance imaging of pelvis (MRI) revealed irregular thickening of rectum with perirectal lymphadenopathy (Figure 1). Preoperative metastatic work-up was negative. She then underwent abdominoperineal resection (APR) with colostomy. Histopathological examination revealed high grade, poorly differentiated, diffuse signet ring cell type adenocarcinoma and was staged T4N2M0. Post-operative contrast enhanced computed tomography (CECT) abdomen revealed multiple heterogeneous peripherally enhancing thickenings with central necrosis in presacral space posterior to cervix and vagina with ill distinct interface and multiple pelvic, retroperitoneal, preaortic and left paraaortic lymphadenopathy (Figure 2). In view of rapidly progressive disease patient was planned for adjuvant chemotherapy with modified FOLFOX-6 regimen at 3-weekly interval. After 5<sup>th</sup> cycle of chemotherapy, patient complained severe itching and swelling in the region of lower abdomen and pelvis. Local examination revealed diffuse nodular lumps with oedema in lower abdomen and pelvis with tense and shiny overlying skin (Figure 3). There was no associated erythema or scaling. On palpation a woody hard induration was appreciated all over the lower abdomen and pelvis. Per-abdomen examination did not reveal any clinically evident organomegaly. Skin biopsy revealed infiltration of the whole skin with carcinomatous cells confirming the diagnosis of carcinoma en cuirasse.

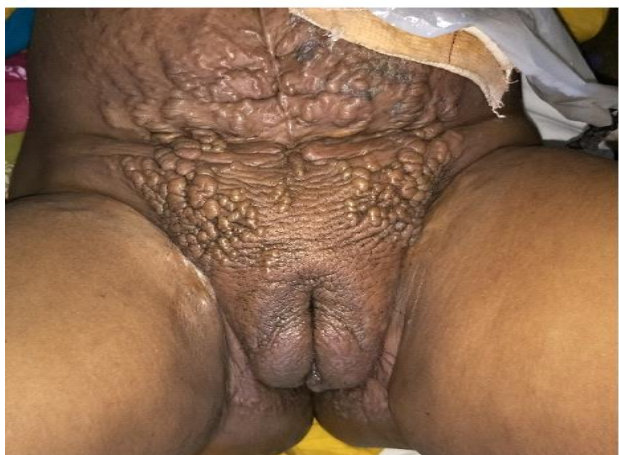Metastatic work-up was negative. Patient refused any further treatment and was kept on supportive treatment but succumbed 2 months later.



**Figure 1: Preoperative MRI abdomen. (A) Sagittal image showing length of rectal growth and (B) axial image showing increased rectal wall thickness.**



**Figure 2: Postoperative CECT abdomen. (A) Axial image showing diffuse infiltration of rectal tumor into surrounding structures and (B) sagittal image showing pre-sacral space invasion of tumor and lymph nodes.**



**Figure 3: Diffuse cutaneous lesions involving lower abdomen and pelvic region.**

## DISCUSSION

Velpeau in 1838 first coined the term carcinoma en cuirasse based upon its resemblance to the steel breastplate of cuirassier i.e. cavalry soldier.<sup>5</sup> Breast cancer is the most common primary associated with cancer en cuirasse where it usually presents as local tumour relapse post mastectomy or as a primary presenting feature.<sup>1,6,7</sup> Cutaneous metastases can manifest at a local surgical site or at a remote site. Melanoma, breast, and upper respiratory tract malignancies (oral cavity, nasal sinuses, and larynx) are the most common primary malignancies associated with skin metastasis.<sup>6</sup>

Cutaneous metastasis develops in 0.7-9.0 % of all malignancies, out of which less than 4 % arise from abdominal malignancies.<sup>8-10</sup> Mucinous variant of rectal adenocarcinoma is found to be more likely associated with cutaneous involvement.<sup>11</sup>

A large retrospective study conducted on 7316 cancer patients included 772 patients of colorectal cancer revealed that only 4 patients (.05 %) had cutaneous involvement at the time of diagnosis.<sup>7</sup> Another study included 4020 patients with metastatic disease, 18 (4.4 %) out of 413 patients of metastatic colon cancer had skin metastasis. Local metastases at the site of abdominal incision was documented in 11 out of 18 patients.<sup>6</sup>

Several mechanisms have been implicated in the pathophysiology of cutaneous metastasis. Lymphatic and hematogenous spread, direct extension, or implantation during surgery are the various routes of metastatic spread of adenocarcinoma to the skin and subcutaneous tissue.<sup>12,13</sup> An average survival of only 18 months is seen in colorectal cancer patients with cutaneous metastases.<sup>6</sup> Young colorectal cancer patients present with more advance and aggressive diseases in spite of their better survival compared to the elderly.<sup>14</sup>

Cutaneous metastases infrequently occurs as the first sign of malignancy but they can be early indicators of metastatic disease that can precede metastasis to other organs as in our patient.<sup>15</sup> During follow-up evaluation in colorectal cancer patients all areas of their skin should be inspected, to recognize any signs of un-resolving skin lesions for early detection and histopathological examination to rule out metastases.

A thorough evaluation of any new skin nodule is mandatory especially at the site of surgical scar. Invariably carcinoma en cuirasse symbolize advanced disseminated disease with poor prognosis hence in all patient's palliative management is pertinent. Palliative surgical excision can be performed in very severe cases though it does not confer any survival benefit. There is currently no consensus on the effectiveness of various treatment modalities as there are too few reported cases to make any conclusion.

## CONCLUSION

Present case is probably the first reported case in English literature occurring in a young female patient with such aggressive disease and rapid progression. Tumour implantation in present case was most likely due to skin trauma during retraction of the bulky tumour thus providing a bed for tumour implantation. Hence utmost care must be taken to not injure the adjacent skin during surgical excision so as not to allow raw areas for tumour seeding. This case highlights the potential of aggressive cutaneous metastases i.e. cancer en cuirasse in patients of rectal cancer for clinician's awareness.

### *Declaration of patient consent*

The authors certify that they have obtained all appropriate patient consent forms. In the form the patients has/have given his/her/their consent for his/her/their images and other clinical information to be reported in the journal. The patients understand that their names and initials will not be published and due efforts will be made to conceal their identity, but anonymity cannot be guaranteed.

*Funding: No funding sources*

*Conflict of interest: None declared*

*Ethical approval: Not required*

## REFERENCES

1. Cruz RG, Kim CC. Tumor invasion of the skin. *Dermatologic Clin.* 2008;26:89-102.
2. McKee PH. Cutaneous metastases. *J Cutan Pathol.* 1985;12:239.
3. Sarid D, Wigler N, Gutkin Z, Merimsky O, Leider-Trejo L, Ron IG. Cutaneous and subcutaneous metastases of rectal cancer. *Int J Clin Oncol.* 2004;9:202-5.
4. Nshan D, Muller ML, Falco BM, Reichenberger S, Szeimies RM, Tuderman LB. Cutaneous metastases of visceral tumours: A review. *J Cancer Res Clin Oncol.* 2009;135:1-4.
5. Savatard L. Cancer en cuirasse. *Br J Dermatol Syphilis.* 1943;55:31-9.
6. Lookingbill DP, Spangler N, Helm KF. Cutaneous metastases in patients with metastatic carcinoma: a retrospective study of 4020 patients. *J Am Acad Dermatol.* 1993;29:228-36.
7. Lookingbill DP, Spangler N, Sexton FM. Skin involvement as the presenting sign of internal carcinoma. A retrospective study of 7316 cancer patients. *J Am Acad Dermatol.* 1990;22:19-26.
8. Gates O. Cutaneous metastases of malignant disease. *Am J Cancer.* 1937;30:718-30.
9. Spencer PS, Helm TN. Skin metastases in cancer patients. *Cutis.* 1987;39:119-21.
10. Gmitter TL, Dhawan SS, Phillips MG, Wiszniak J. Cutaneous metastases of colonic adenocarcinoma. *Cutis.* 1990;46:66-8.
11. Dehal A, Patel S, Kim S, Shapera E, Hussain F. Cutaneous Metastasis of Rectal Cancer: A Case Report and Literature Review. *Perm J Winter.* 2016;20:74-8.
12. Kauffman CL, Sina B. Metastatic inflammatory carcinoma of the rectum: tumor spread by three routes. *Am J Dermatopathol.* 1997;19:528-32.
13. Mathew G, Watson DI, Ellis T, Young ND, Rofe AM, Jamieson GG. The effect of laparoscopy on the movement of tumor cells and metastasis to surgical wounds. *Surg Endosc.* 1997;11:1163-66.
14. Connell OJB, Maggard MA, Liu JH, Etzioni DA, Livingston EH, Ko CY. Do young colon cancer patients have worse outcomes. *World J Surg.* 2004;28:558-62.
15. Tan KY, Ho KS, Lai JH, Lim JF, Ooi BS, Tang Cl, et al. Cutaneous and subcutaneous metastases of adenocarcinoma of the colon and rectum. *Ann Acad Med Singapore.* 2006;35:585-7.

**Cite this article as:** Gupta P, Nigam A, Dhull AK, Mittal A. A peculiar case of cancer en cuirasse in adenocarcinoma rectum. *Int J Sci Rep* 2020;6(5):190-2.