

## Case Report

# Wilkie's syndrome in an adolescent female patient

Bandar Idrees A. Ali<sup>1\*</sup>, Khuloud Omar Bukhari<sup>2</sup>, Abdullah Saeed Alzahrani<sup>1</sup>

<sup>1</sup>Department of Surgery, Prince Sultan Military Medical City, Riyadh, Saudi Arabia

<sup>2</sup>Ministry of Health, Riyadh, Saudi Arabia

**Received:** 21 July 2020

**Accepted:** 08 September 2020

### \*Correspondence:

Dr. Bandar Idrees A. Ali,

E-mail: [biaa1003@yahoo.com](mailto:biaa1003@yahoo.com)

**Copyright:** © the author(s), publisher and licensee Medip Academy. This is an open-access article distributed under the terms of the Creative Commons Attribution Non-Commercial License, which permits unrestricted non-commercial use, distribution, and reproduction in any medium, provided the original work is properly cited.

### ABSTRACT

One of the rare cases of the upper gastrointestinal tract obstruction is superior mesenteric artery syndrome (SMAS) but potentially life-threatening if not recognized early. It is due to loss of fat pad between the aorta and SMA which will lead to a compression of the third portion of the duodenum. It has a different angle which will lead to different presentations as well as severity. We are reporting the 15 year-old (y/o) female who is medically free, presented to the emergency department (ED) complaining of severe colicky epigastric abdominal pain for the last 5 days in the epigastric area. The diagnosis of SMAS was made after clinical and radiological investigation. After proper supportive resuscitative measures, definitive management of the surgery was done by laparoscopic approach (duodenojejunostomy). The diagnosis of SMA syndrome is considered challenging due to many presentations and might be confused with other clinical conditions. Unless early diagnosed and treated, the outcome might be catastrophic. Medical treatment is attempted first in many cases depending on the severity and presentation but if failed, surgery will be the best option.

**Keywords:** Superior mesenteric artery syndrome, Cast syndrome, Wilkie's syndrome, Mesenteric root syndrome

### INTRODUCTION

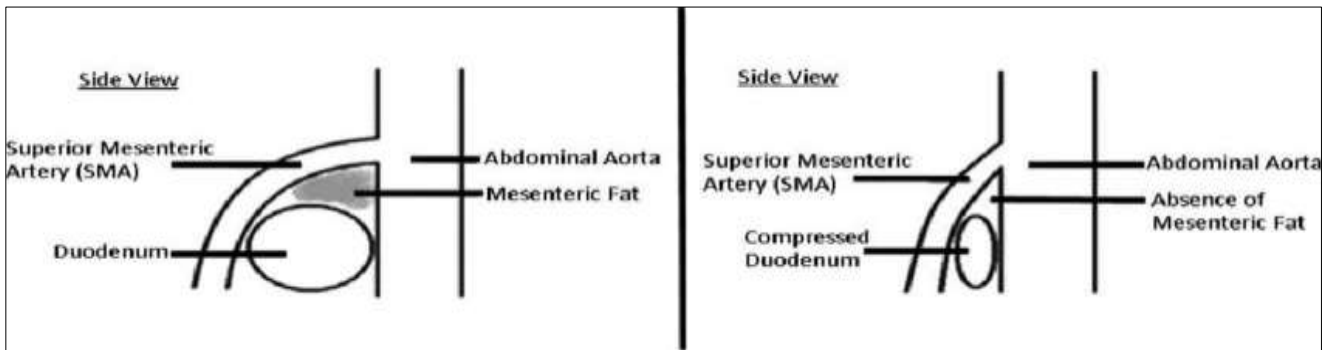
Wilkie's syndrome or superior mesenteric artery syndrome (SMAS) is also known as intermittent arterio-mesenteric occlusion, mesenteric root syndrome, cast syndrome, and chronic duodenal ileus.<sup>1</sup>

In 1927, Wilkie published the first comprehensive series of 75 patients but it was first described in 1861 by Rokitsansky.<sup>2,3</sup> It is a rare condition, and the exact incidence of SMAS is unknown but found in the literature ranging between 0.013 to 0.3%.<sup>4</sup>

The pathophysiology of this syndrome is a complex entero-vascular disorder which is due to loss of fat pad. The third portion of the duodenum is compressed between the abdominal aorta (AA) and the overlying superior mesenteric artery (Figure 1). Besides the clinical impression needed for the diagnosis, abdominal imaging is considered the cornerstone for accurate diagnosis

especially computed tomography (CT) for the abdomen. Calculation of the angle of AA and SMA as well as the aorto-mesenteric distance is particularly important to have an accurate diagnosis. Normally, the angle between AA and SMA is in the range of 38°-56°, while SMAS is typically caused by an angle of 6°-25° due to thinning or loss of retroperitoneal fat. The normal measures in the aortomesenteric distance is 10-20 millimeters, while the angle found in the SMAS patients is 2-8 millimeters.<sup>5</sup> In some children and low body weight adults, a narrow SMA angle alone is not considered a sufficient measure to confirm the diagnosis of SMAS and might be found asymptomatic.

The presentation varies among the SMAS patients, acutely or chronically, mild, moderate, or severe, typical or atypical symptoms. With these wide symptoms and presence of a lot of predisposing factors, the diagnosis will be challenging and might be confused with other medical conditions. Eventually, it might lead to a poor outcome.



**Figure 1: (a) Side view of the normal anatomy between the 3rd portion of the duodenum and aorto-mesenteric root, and (b) pathology.**

**CASE REPORT**

A 15 year-old (y/o) female who was medically free, presented to the emergency department (ED) complaining of colicky abdominal pain for the last 5 days in the epigastric area which was not radiating, getting worse with time, aggravated by laying down and oral intake; and relieved by a knee to chest position and fasting. The severity of pain was 7 out of 10. It was associated with multiple times of vomiting, decreased oral intake, weight loss, and constipation. She denied any history of difficulty in swallowing or vomiting blood, fever, or change in her urinary symptoms.

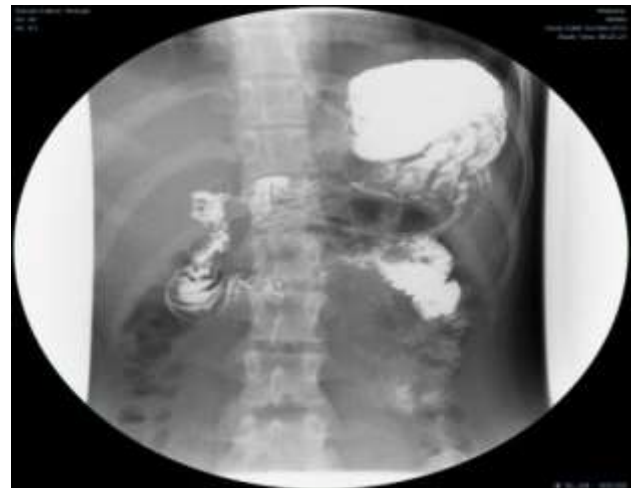The patient had experienced this pain multiple times in the last 5 years, each time she had been treated conservatively either by hospital admission or discharged home. The past medical and surgical history is unremarkable. She was single, a student in high school, and living with her family. There was no history of malignancy or the same complaint within her family.

Her physical examination revealed an alert, oriented, and conscious person but looked in pain, dehydrated, and underweight with body mass index (BMI) of 20 kg/m<sup>2</sup>. Her vital signs were within an acceptable range. On abdominal inspection, there was no sign of scar or wound indicating previous surgery, and no swelling indicating hernia or discoloration. On palpation, the abdomen was soft and lax with no tenderness, and guarding but fullness, especially in the epigastric area. The systematic examination was unremarkable.

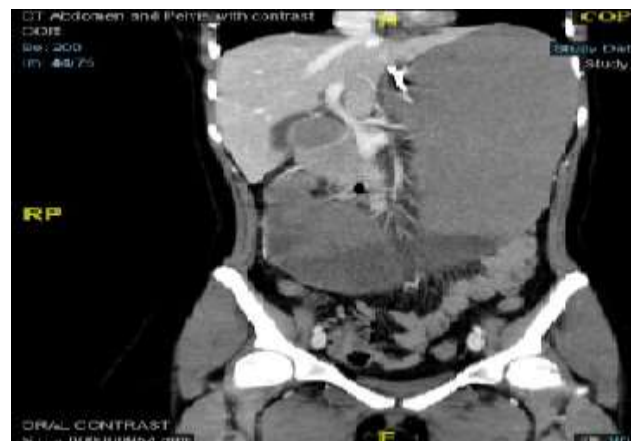All laboratory investigations revealed results within the normal range. Radiological imaging with abdominal gastrografen follow-through study showed esophageal motility disturbance with reduced peristalsis, transient delayed emptying of the second to the third part of the duodenum, and improvements with changing position without proximal dilatation (Figure 2). The combination suggests SMAS.

CT abdomen and pelvis with contrast showed severely dilated stomach and duodenum up to the level of the third

part, which was severely compressed as it is passed between the superior mesenteric artery and the aorta (Figure 3). The aortomesenteric angle was approximately 18.5 degrees (Figure 4 and 5). There was no intra-abdominal free air. Also, no free or localized fluid collection was present.



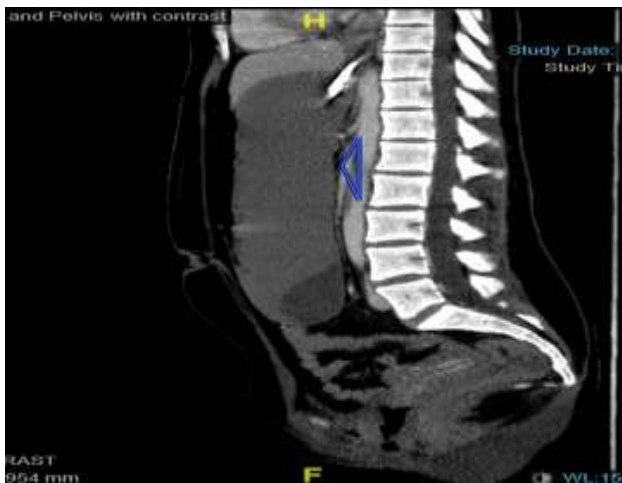**Figure 2: Barium follow through showing transient delayed emptying of the second to the third part of the duodenum.**



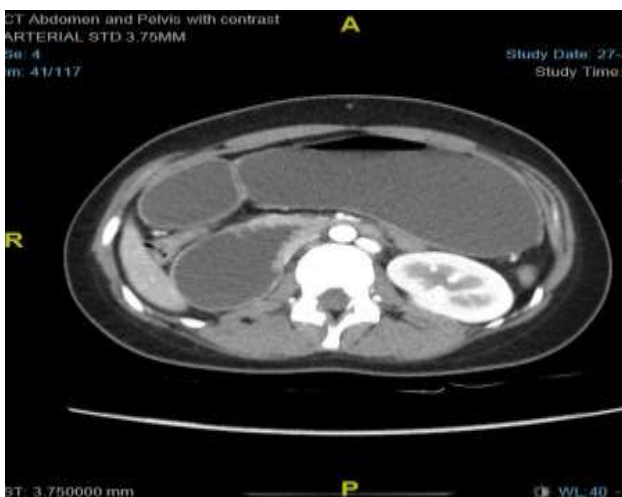**Figure 3: Pre-operative CT coronal view.**

The SMA, inferior mesenteric artery (IMA) and celiac artery were well opacified with contrast. The small bowel loops were collapsed and displaced inferiorly to the left side, not showing the feature of bowel ischemia.

The relation between SMA and SMV were normal, and there was no malrotation. The liver, spleen, adrenals, and kidneys were unremarkable. The pancreas was compressed and displaced, occupying the C-loop of the duodenum and extended posterior to the second part of the duodenum, however, it does not encircle the duodenum. Visualized bony structures appeared grossly unremarkable.



**Figure 4: CT sagittal (lateral) view.**

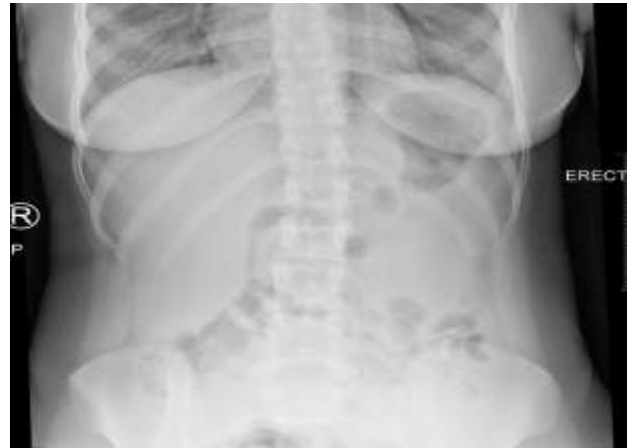

**Figure 5: Preoperative CT coronal view.**

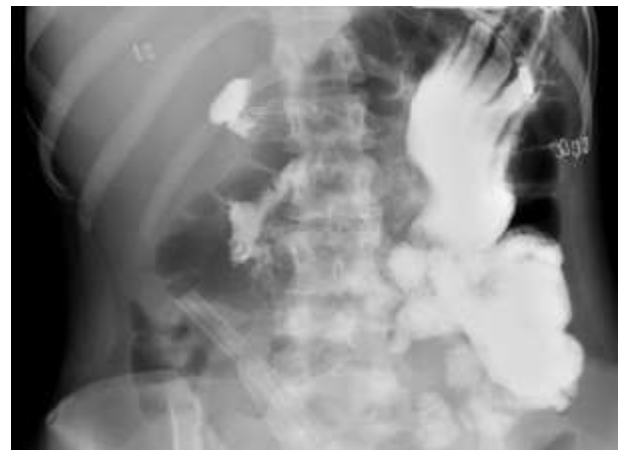### *Hospital course*

The patient was admitted to the general ward with an established diagnosis of SMA syndrome. Initial management was started by keeping the patient nil per os (NPO) with intravenous fluid (IVF) to maintain good hydration. A nasogastric tube (NGT) was inserted with an

output of 1500 ml upon insertion to decompress the stomach and relieve the pain.



**Figure 6: Plain abdomen x-ray (erect) post operation.**



**Figure 7: Gastrografin follow through study, post laparoscopic duodenojejunostomy.**

The patient was on daily labs, maintained in good analgesia. Peripherally inserted central line (PICC) line was inserted to provide nutritional supplement to the patient by total parenteral nutrition (TPN). Patient was prepared for an operative room on the fifth day of admission. The patient underwent uneventful laparoscopic duodeno-jejunosotomy done side-side between the 3<sup>rd</sup> part of the duodenum and proximal jejunal loop. Postoperatively, the patient was recovering very well during the hospital stay, remained NPO, and on TPN 72 hours post-operation. The patient started on sips of water on day 3. NGT was removed on day 4 and the diet was advanced to full liquid and she was tolerating very well adequate amount to her daily need with no vomiting or abdominal pain and TPN was stopped. The drain was removed on day 5 and the patient was discharged home on day 7 in good condition. The patient was seen in the clinic 1, 2, and 8 weeks after surgery. She was doing great, improving day by day, no more vomiting, tolerating orally well, gaining weight, and had a good lifestyle.

Follow up radiological imaging showed the same clinical improvement picture and excellent interval recovery. Plain abdominal x-ray (erect) post operation denoted nonspecific distribution of bowel gases with no bowel dilatation air-fluid level or air under the diaphragm. No obvious calcific density was noted at kidney, ureter and bladder (KUB) region (Figure 6). Gastrografin follow through study, post laparoscopic duodenojejunostomy denoted that the contrast was given by a NG tube. Normal flow of contrast was seen on the stomach to the jejunal loops. No evidence of any obstruction or leakage of contrast was noted. Postsurgical changes were also seen (Figure 7).

## DISCUSSION

The SMAS presentations are varied and broad, depending on the severity, onset, and underlying cause. Most of the time, the symptoms are non-specific, including vague and dull central abdominal pain, abdominal distension, early satiety, vomiting, and nausea. Food fear, loss of appetite, and weight loss can occur in chronic conditions.

A long history of abdominal complain among the SMAS patients, usually lead to difficulty of the disease diagnosis due to development of poor nutritional status as well the psychological burden and loss of trust of improvement from the patient towards medical care providers. The long-standing form of the SMAS usually has the worst outcome due to irreversible damage to the gastrointestinal wall and secondary motility disorder development. The presence of wide differential diagnosis i.e. bowel obstruction, adhesion, paralytic ileus, pancreatic disorders, intussusception, and intestinal malrotation will add more challenges to reach the diagnosis.

A high index of suspicion in the high-risk patient will facilitate and lead to early pick up this disease. Those patient include retroperitoneal tumors i.e. (sarcoma, genitourinary tumor, lymphoma, and vascular), loss of appetite in eating disorder patient i.e. (anorexia nervosa and bulimia), patient with severe depression and decrease oral intake, gastrointestinal malabsorptive enteropathy, underweight or thin patient with low body mass index (BMI), spinal deformities, lumbar lordosis or scoliosis, or bedridden patient with muscle wasting and patients with abdominal trauma, rapid linear adolescent growth spurt, starvation, catabolic states (as with cancer and burns), and history of neurological injury.<sup>7-9</sup>

Rarely, a patient may have a congenitally short ligament of Treitz suspending the duodenum in an abnormally cephalad position. A case report of identical twins with this disorder and another case diagnosed in utero suggest there may be a genetic predisposition in some patients.<sup>10,11</sup>

One study showed around 40% of SMAS patients consider idiopathic i.e. no definite or obvious cause.<sup>12</sup> This will lead to making the SMAS as a primary diagnosis is not a straightforward issue. Needs clinical, radiological,

invasive, and non-invasive investigational tools. The pathognomic features may not appear early in the investigation, which depends on the onset and chronicity of the disease. Although plain abdominal films are frequently nonspecific, it might show dilated proximal bowel loop, distended stomach and if oral contrast is given may show delay gastric emptying and abrupt contrast flow at the duodenal level. Transabdominal ultrasound (US) is a low cost, non-invasive tool to evaluate the mesenteric artery anatomy, which can identify and measure the aorto-mesenteric angle.<sup>13</sup>

Computed tomographic (CT) and magnetic resonance (MR) arteriography have largely replaced conventional arteriography since they are noninvasive and provide additional anatomic detail such as the amount of intra-abdominal and retroperitoneal fat.<sup>14,15</sup> However, arteriography may be needed if a diagnosis remains unclear.

Treatment depends on the presentation, acute or chronic nature and urgency. Conservative (medical) or surgical treatment are the options. Overall, the medical treatment has a response to up to two-thirds of the cases according to some literature.<sup>16,17</sup> The goals of conservative treatment of superior mesenteric artery syndrome are to relieve obstructive symptoms and reversal of any precipitating factors. However, if surgery has altered the anatomy, the likelihood that conservative therapy will be successful is low.

Good rehydration, correction of electrolyte abnormalities, nutritional support is considered the major component of therapy and psychiatric evaluation and support.

Failure of medical treatment should not delay or hesitate for urgent surgical intervention. It has been described by many surgical options for the treatment of superior mesenteric artery syndrome. These include Strong's procedure (a division of ligament of treitz gastrojejunostomy, and duodenojejunostomy with or without division or resection of the fourth part of the duodenum).<sup>18</sup>

The most common and successful operation for SMA syndrome is duodenojejunostomy, which was first proposed in 1907 by Bloodgood which can be done open or laparoscopically.<sup>19-21</sup>

Patients are followed for resolution of their preoperative symptoms and weight gain is monitored.

There are few reports of long-term outcomes in patients with superior mesenteric artery syndrome who have undergone surgery. One of the largest series included 18 patients who were followed seven years after surgery.<sup>21</sup> Weight loss had been corrected in all patients. However, symptoms were essentially unchanged except for vomiting, which was significantly decreased.

Each of the surgical approaches has advantages and disadvantages. Strong's procedure maintains the integrity of the bowel; however, failure occurs in up to one-fourth of patients. Gastrojejunostomy decompresses the stomach but the failure to relieve the duodenal obstruction may result in recurrent symptoms requiring a second procedure and the unrelieved obstruction may result in blind loop syndromes or peptic ulceration. Duodenojejunostomy is generally accepted as having superior results to both Strong's procedure and gastroenterostomy. Duodenojejunostomy with the division of the fourth part of the duodenum establishes bowel continuity and minimizes the issues associated with a blind loop.<sup>21</sup>

## CONCLUSION

Wilkie's syndrome or SMAS is still an uncommon disease that arises from the compression of the third part of the duodenum by the superior mesenteric artery. Although the medical treatment shows a favorable result, surgical management considers superior if the disease is recognized early and failed medical management. Late diagnosis may lead to irreversible motility disorder which might lead to poor outcomes even after surgical intervention.

*Funding: No funding sources*

*Conflict of interest: None declared*

*Ethical approval: Not required*

## REFERENCES

- Laffont I, Bensmail D, Rech C, Prigent G, Loubert G, Dizien O. Late superior mesenteric artery syndrome in paraplegia: case report and review. *Spinal Cord.* 2002;40(2):88-91.
- Welsch T, Büchler MW, Kienle P. Recalling superior mesenteric artery syndrome. *Dig Surg.* 2007;24(3):149-56.
- Rokitansky C. *Handbuch der pathologischen anatomie.* Vienna: Branmiller and Siedel. 1842.
- Aljarad Z, Mahli N, Nasser M, Alobied M, Alkhaled M, Hamoud Alhussein MWH, et al. Superior Mesenteric Artery Syndrome Caused by Weight Loss in a Malnourished Syrian Man. *Gastroenterol Rep.* 2019;7:223-5.
- Shetty AK, Schmidt-Sommerfeld E, Haymon ML, Udall JN. Radiologica case of the month: Denouement and discussion: Superior mesenteric artery syndrome. *Arch Fam Med.* 2000;9(1):17.
- Choi JW, Lee JY, Cho HG. Superior Mesenteric Artery Syndrome Treated with Percutaneous Radiologic Gastrojejunostomy. *Korean J Gastroenterol.* 2016;67:321.
- Roy A, Gisel JJ, Roy V, Bouras EP. Superior Mesenteric Artery (Wilkie's) Syndrome as a Result of Cardiac Cachexia. *J Gen Intern Med.* 2005;20:3-4.
- Falcone KL, Garrett KL. Superior Mesenteric Artery Syndrome After Blunt Abdominal Trauma: A Case Report. *Vasc Endovascular Surg.* 2010;44(5):410-2.
- Biank V, Werlin S. Superior mesenteric artery syndrome in children: A 20-year experience. *J Pediatr Gastroenterol Nutrition.* 2006;42(5):522-5.
- Iwaoka Y, Yamada M, Takehira Y, Hanajima K, Nakamura T, Murohisa G, et al. Superior mesenteric artery syndrome in identical twin brothers. *Intern Med.* 2001;40:713.
- Caspi B, Deutsch H, Grunshpan M, Flidel O, Hagay Z, Appelman Z. Prenatal manifestation of superior mesenteric artery syndrome. *Prenat Diagn.* 2003;23:932.
- Akin JT, Gray SW, Skandalakis JE. Vascular Compression of the Duodenum: Presentation of Ten Cases and Review of the Literature. *Surgery.* 1976;79:515-22.
- Neri S, Signorelli SS, Mondati E, Pulvirenti D, Campanile E, Di Pino L, et al. Ultrasound imaging in diagnosis of superior mesenteric artery syndrome. *J Intern Med.* 2005;257:346-51.
- Christopher TB, Mark AG. Unusual Causes of Recurrent Abdominal Pain. *Emerg Med.* 2006;38(5):11-8.
- Murphy DJ, Aghayev A, Steigner ML. Vascular CT and MRI: a practical guide to imaging protocols. *Insights Imaging.* 2018;9:215-36.
- Shin MS, Kim JY. Optimal duration of medical treatment in superior mesenteric artery syndrome in children. *J Kor Med Sc.* 2013;28(8):1220-5.
- Biank V, Werlin S. Superior mesenteric artery syndrome in children: A 20-year experience. *J Pediatr Gastroenterol Nutrition.* 2006;42(5):522-5.
- Merrett ND, Wilson RB, Cosman P, Biankin AV. Superior Mesenteric Artery Syndrome: Diagnosis and Treatment Strategies. *J Gastrointest Surg.* 2009;13:287.
- da Costa KM, Saxena AK. Laparoscopic Options in Superior Mesenteric Artery Syndrome in Children: Systematic Review. *J Pediatr Endosc Surg.* 2019;1:53-7.
- Baltazar U, Dunn J, Floresguerra C, Schmidt L, Browder W. Superior mesenteric artery syndrome: an uncommon cause of intestinal obstruction. *South Med J.* 2000;93(6):606-8.
- Ylinen P, Kinnunen J, Höckerstedt K. Superior mesenteric artery syndrome. A follow-up study of 16 operated patients. *J Clin Gastroenterol.* 1989;11(4):386-91.

**Cite this article as:** Ali BIA, Bukhari KO, Alzahrani AS. Wilkie's syndrome in an adolescent female patient. *Int J Sci Rep* 2020;6(11):456-60.